

Proximal Metatarsal Opening Wedge Osteotomy: PMOW - Arthrex LPS System

Paul S. Shurnas, M.D. - Boone Hospital Center and Columbia Orthopaedic Research Institute
Troy Watson, M.D. - Las Vegas Foot & Ankle Institute
Scott Fitzner, DPM - The Forest Park Podiatric Residency Program
James Ronan, MS - Boone Hospital Center and the Columbia Orthopaedic Research Institute

Objective

The purpose of this study was to present the 2 year minimum follow-up results of the proximal opening wedge (PMOW) osteotomy using the Arthrex LPS 1st metatarsal POW system.

Methods and Materials

84 patients (90 feet) underwent PMOW osteotomy with distal bunionectomy between November 2004 and November 2007. Pre and postoperative clinical examinations, visual analogue score (VAS) for pain, activity level, patient derived subjective satisfaction of the foot and surgery, and radiographic measurements were obtained and evaluated retrospectively. Patients were instructed to weight-bear as tolerated immediately following surgery in a cam walking boot and were protected in a figure eight dressing to maintain alignment for 6 weeks.

Results

There were 78 patients (93%) and 84 (93%) feet available for follow-up. Mean follow-up was 2.4 years (range 2.0-3.2 years) from the time of the index surgery. The mean pre-op VAS score was 5.85 (± 2.18) compared with postoperative scores of 0.43 (± 0.94) and 0.52 (± 0.89) at 3 and 6 months follow-up visits respectively. The mean 1-2 IMA preoperatively was 14.5° ($\pm 3.3^\circ$) compared with postoperative measurements at a minimum of 2 years after the index surgery of 4.6° ($\pm 2.8^\circ$) including two feet with 2° or more increased 1-2 IMA. The mean hallux valgus angle (HVA) improved from a mean of 30° (range of 22-64°) preoperatively to 10° (range of (-) 15 to 18°) at a minimum of 2 years including four patients that had valgus drift of 5° or more (range 5-15°). The 1-2 IMA and HVA angles can be seen graphically in Figure 1. A pre-op and two year radiograph of the same patient can be seen in Figure 2. The mean time to radiographic union was 5.9 weeks (range 4-14 weeks). There was one nonunion, one delayed union, hallux varus in four patients, and no instances of hardware failure. There was no significant difference in mean preoperative

(74.8° ± 11) compared to postoperative (67.9° ± 10) total MTP joint range of motion. 90 percent of patients reported good to excellent self-rated results after the index surgery.

Figure 1: 1-2 IMA and HVA data

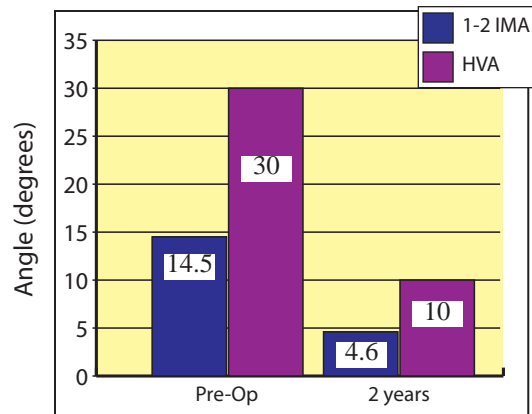
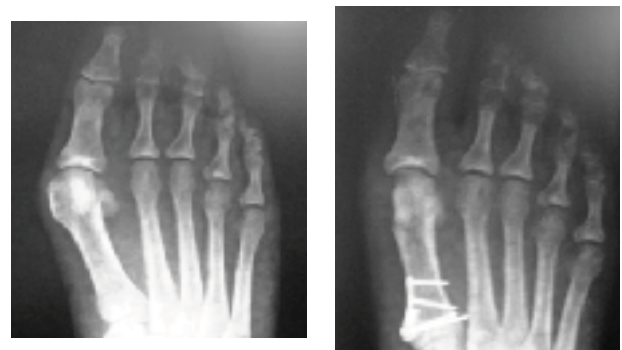

Figure 2: Pre-op and 2 year radiograph



Conclusion

PMOW osteotomy, when fixed with the Arthrex LPS system, is near ideal in terms of reliable, predictable correction and healing. There has been a low incidence of complications - most of which were minor.