

Histological Analysis of the Vented BioComposite SwiveLock in the Canine Humerus

Arthrex Research and Development

Objective

This is a pilot study (N=2) to evaluate the osteogenic response of the 5.5 mm vented BioComposite SwiveLock in the canine model. This study was performed by Dr. J.L. Cook, et al. in his Comparative Orthopaedic Laboratory at the University of Missouri.

Methods and Materials

The BioComposite SwiveLock vented anchors were inserted into the proximal humerus, anterior to the attachment site of the infraspinatus and teres minor. Animal euthanasia was performed after eight (8) weeks of healing and the embedded anchors were sectioned and prepped for histological examination. Assessment after eight weeks included histological examination using Goldner's trichrome (bone = green, osteoid = red) and toluidine blue (bone = purple/blue, osteoid = pale blue) histological stains.

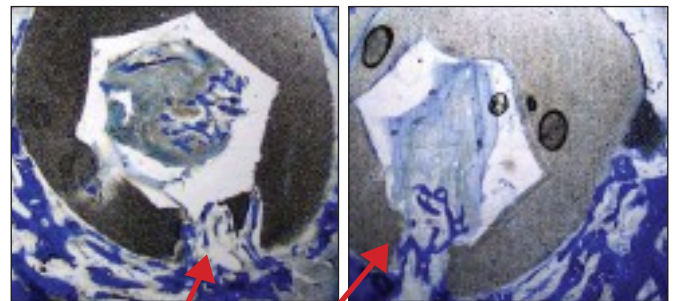
Results

There is evidence of bone formation within the vent channels and central lumen of BioComposite SwiveLock vented anchor. While Figure 1 illustrates the functionality of the anchor, the photomicrographs in Figures 2 and 3 show bony ingrowth through the vents and inner lumen after eight weeks in the canine humerus.

Figure 1: Functional illustration of the vented SwiveLock

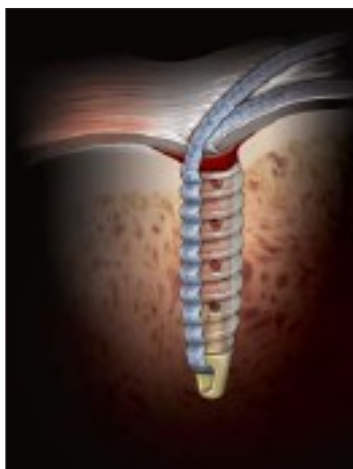

Figure 2: Transverse-anchor view of the vented BioComposite SwiveLock showing new bone formation within the center cannulation and vents (blue = bone, pale blue = osteoid)



Vents

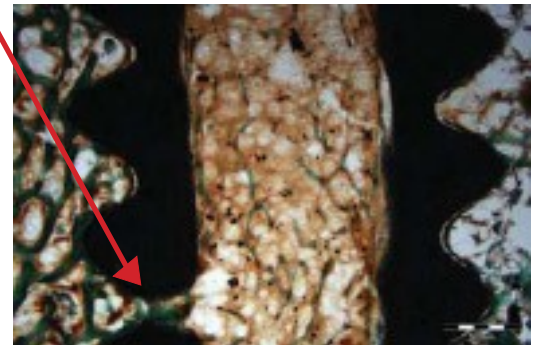


Figure 3: Sagittal-anchor view of the vented BioComposite SwiveLock, illustrating new bone formation within the center cannulation and vents (green = bone, red = osteoid)

Conclusion

While histological analysis shows bone growth within the anchor vents and lumen, due to the small sample size, (N=2) this research should be viewed as pilot in nature. A pivotal study with a larger N and longer implantation end-points will be performed to determine the osteogenic and functional healing response of the vented BioComposite SwiveLock anchor.